

Anti-Inflammatory and Anti-Oxidant Effects of PDE-5 Inhibitor on Experimental Colitis in Rats

Shaza Anwar Al Laham

Department of Pharmacology & Toxicology – Faculty of Pharmacy- Syrian Privet University – Syria.

Department of physiology and medicine – Faculty of Medicine - Syrian Privet University – Syria.

Department of Pharmacology & Toxicology – Faculty of Pharmacy- Damascus University – Syria.

ARTICLE INFO

Article history:

Received: 20 November 2017;

Received in revised form:
19 February 2018;

Accepted: 28 February 2018;

Keywords

Sildenafil,
Ulcerative Colitis,
Acetic Acid,
Glutathione,
Macroscopic,
Histopathological.

ABSTRACT

Ulcerative colitis (UC) is a common and chronic gastrointestinal disorder characterized by intestinal inflammation and mucosal tissue damage. Reactive oxygen species (ROS) play a pathogenic role in UC. The aim was to examine the treatment effect of sildenafil, a cGMP phosphodiesterase inhibitor, in the experimental rat model of UC. Intrarectal instillation of acetic acid (1ml 5% v/v) was used to induce UC. Sildenafil was used at a dose of 10 mg/kg. Rats received treatment for 5 consecutive days. On day 6, the rats were sacrificed, the colon was removed, then the body weight, colon weight/length ratio, tissue glutathione (GSH) concentration, macroscopic, and histopathological evaluations, were performed. The levels of body weight, and colon weight/length ratio was decreased significantly ($P < 0.05$). The glutathione (GSH) concentration was increased significantly ($P < 0.05$). The macroscopic and histopathological parameters were decreased, but it didn't reduce significantly in the Sildenafil treated groups, compared to the acetic acid-treated group. The anti-inflammatory and antioxidant effects of Sildenafil in treating the UC are due to its potential to reduce the colon weight/length ratio, increased GSH, and improving the macroscopic, and histological markers.

© 2018 Elixir All rights reserved.

Introduction

Phosphodiesterase type 5 (PDE-5) is an enzyme that catalyzes cyclic adenosine monophosphate (cAMP) and cyclic guanosine monophosphate (cGMP), which are essential intracellular second messengers regulating many different cellular functions of living cells. PDE-5 specifically breaks down the substrate cGMP [1]. PDE-5 is present in the corpus cavernosum penis, the cells of the smooth muscle of peripheral arteries and veins, the pulmonary and coronary circulation, and platelets and endothelial cells of blood vessels. Therefore, PDE-5 inhibitor drugs can cause systemic hemodynamic changes [2]. Sildenafil binds to the catalytic site of PDE-5 and inhibits the degradation of intracellular cGMP, which causes smooth muscle cell relaxation and vasodilation [1]. By preventing degradation of cGMP in vascular smooth muscle, these inhibitors also enhance arterial vasorelaxant effects of nitric oxide donors (which stimulate cGMP synthesis) [3].

Phosphodiesterase-5 inhibitors, sildenafil, which are usually prescribed to patients with erectile dysfunction or with pulmonary hypertension, have also been shown to exert protective effects that may justify their use in patients with other cardiovascular diseases [4], such as cardiovascular remodeling [5]. Numerous studies have demonstrated that PDE-5 inhibitors have powerful protective effect against myocardial ischemia/reperfusion (I/R) injury, ischemic and diabetic cardiomyopathy, cardiac hypertrophy, Duchenne muscular dystrophy and the improvement of stem cell efficacy for myocardial repair. As well as, PDE-5 inhibitors enhance the sensitivity of certain types of cancer to standard chemotherapeutic drugs [6].

Sildenafil also has protective effects in the CNS by prevents and restores LPS-induced inflammation in astrocytes [7], and reduces renal injury due to ischemia [8]. The previous studies, for the gastrointestinal tract, have shown that sildenafil reduces gastric emptying and small bowel transit in healthy and pathological conditions, and had beneficial effects in the treatment of Irritable bowel syndrome (IBS) in rats [9]. In addition, Sildenafil inhibits the interdigestive motor activity of the antrum and duodenum [10], and has a protective effect for Inflammatory bowel disease (IBD) [11], and for the gastric mucosa against the aggressive effect of indomethacin [12].

Ulcerative colitis (UC) and Crohn's disease (CD), the primary constituents of inflammatory bowel disease (IBD), are precipitated by a complex interaction of environmental, genetic, and immunoregulatory factors [13]. Ulcerative colitis (UC) is a chronic and relapsing inflammatory disorder of the gastrointestinal tract, defined by clinical characteristics such as diarrhea, abdominal pains, weight loss and nausea and by pathological features such as a loss of mucosal integrity and inflammatory cell infiltration [14]. There is evidence for an intense local immune response associated with recruitment of lymphocytes and macrophages followed by the release of soluble cytokines and other inflammatory mediators [15]. In addition to reactive oxygen species (ROS), which cause impairment of cellular membrane stability and cell death by leading lipid peroxidation [16].

The aim was to examine the treatment effect of sildenafil, a cGMP phosphodiesterase inhibitor, in the experimental mouse model of UC. To the best of our knowledge, no scientific data regarding the activity of

Tele:

E-mail address: lahamshaza@gmail.com

Sildenafil on UC as treatment is available in the literature. Therefore, this work has been undertaken.

Material & Method

Animals

Wister rats weighing (250-300g) were housed under a 12-h light–dark cycle at a constant ambient temperature (22 to 25°C), with normal rat chow and water *ad libitum*. All rats were deprived of food for 48 h prior to the experimental procedure but were allowed free access to tap water. All methods performed in this study were in accordance with regulatory guidance on the care and use of experimental animals. Eighteen Wister rats were divided into three groups of six members each. The groups were divided into normal control group (NC), acetic acid (CC) control, and Sildenafil treated group(S). Group (NC) was received physiological saline intrarectally, following the administration of oral gavage syringe; Group (CC) (colitis control) received 1 ml acetic acid 5% (Merck company) intrarectally, following the administration of saline orally [17]; Group (S) received 1 ml acetic acid 5% intrarectally, following the administration of Sildenafil (10 mg/kg/day, orally), obtained from *Santa Cruz*. Biotechnology, suspended in normal saline [12], once daily for 5 consecutive days, starting 24 h after the induction of colitis.

Induction of colitis

Following 24 h fasting (receiving nothing except water) and under light ether anesthesia, colonic inflammation was induced by acetic acid. Groups (CC) and (S) were treated with 1 ml acetic acid 5% enema, through a polypropylene trocar cannula which was inserted into the colon via the anus for 8 cm [17]. Tissues were kept for 30 sec with acetic acid, then washed with warm normal saline. Group (NC) as treated with 1 ml physiological saline instead of acetic acid with the same method to serve as the control group [18].

Assessment of colitis

During the study, rats were checked daily for body weight, behavioral changes, food intake, rectal bleeding and stool consistency. The body weight of animals was measured at regular time intervals from day 0 to 5, change of body weight (%) was calculated, also. All the rats in each group were sacrificed on the 6th day under deep ether anesthesia. The distal colon was excised, opened longitudinally, and rinsed with saline solution. The distance from the colorectal junction to the anus, the length (cm) and weight (mg) of the colon, were measured, from which weight/length (mg/cm) ratios obtained, as indirect marker of inflammation was calculated. Then the colon was sectioned into two pieces, after macroscopic examination, one was stored at -80°C for biochemical analysis (tissue GSH levels), and the other was fixed in 10% buffered formalin solution for histopathological studies.

Measurement of Reduced glutathione levels

Glutathione Assay Kit (Abnova Chemical Company, (Taiwan)) for direct assay of reduced glutathione in colonic tissue was used. Colonic tissue samples were frozen in liquid nitrogen, stored at -80°C until the time of assay. Colon GSH levels were determined as previously described by [19], based on the reaction of 5, 5-dithiobis-(2-nitrobenzoic acid) (DTNB) with the glutathione present to form a yellow product. The optical density (OD) measured at 412 nm is directly proportional to glutathione concentration in the sample by using microplate reader (Elisys Uno Human, Germany). The glutathione content was expressed as $\mu\text{M/g}$ tissue.

Macroscopic examination

To evaluate the macroscopic damage, the colon was examined visually immediately and by a magnifying lens for gross inflammatory changes. The damage [colon mucosal damage index (CMDI)] in CC-induced colitis was scored on the following scale of 0 to 4 according to the criteria described by Amirshahrokhi: 0=no inflammation; 1=swelling or redness; 2=swelling and redness; 3=one or two ulcers; 4=more than two ulcers or one large ulcer; 5=mild necrosis; 6=severe necrosis [17].

Histopathological examination

Colon sections were fixed 15% formalin then put for 24 h in the decal. Samples were then cut into several sections and embedded into paraffin wax blocks. Tissues were stained with hematoxylin and eosin and were mounted and observed microscopically for histopathological changes by a pathologist in the blinded fashion.

Histopathologically were assessed by using the following score according to Medhi *et al* [20]: 0= normal ; 1=mild mixed infiltrates in the lamina propria ; 2=focal superficial ulceration of mucosa only, moderate cryptitis and crypt abscess ; 3=deep ulceration penetrating colonic wall through mucosa till muscularis mucosa and severe inflammation ; 4=necrosis through the large bowel wall.

Statistical Analysis

Data analyses were achieved using Prism (Version 5) statistical package. Data were presented as means \pm standard deviation (SD). For parametric data, One-way analysis of variance (ANOVA) was used followed by Tukey-Kramer multiple comparison tests. Lesion score and histological score (non-parametric values) analyzed using the Kruskal–Wallis nonparametric analysis of variance with Dunn's multiple comparison tests. P values less than 0.05 were considered Statistically significant.

Results

Effect of sildenafil on the animals' food intake, weight, and well-being

Acetic acid treated rats were agitated and manifested decreased food intake, general malaise, severe diarrhea, progressively body weight loss with weakness, and hematochezia. Treatment with Sildenafil corrected diarrhoea and improved their general condition and well-being.

The body weight of the group (CC) had significantly decreased by (-16.52%) ($p<0.05$), Compared with that of the (NC) group which revealed increase in the body weight (+6.81%). Also, the body weight of the (S) group was significantly reduced by (-2.31%) Compared with that of the (CC) group ($p<0.05$). (Figure1).

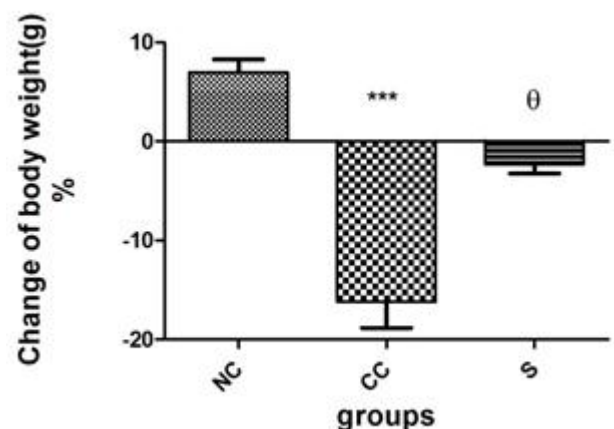


Figure 1. Effects of Sildenafil on colonic body weight.

Each column represented as the mean±SD. *** $P<0.05$, compared to the NC group; θ $P<0.05$, compared to the CC group. NC, control group; CC, Acetic acid; S, Sildenafil.

Colon weight / length ratio:

The rats in the (CC) group showed a significant increase in the colonic weight/length ratio ($p<0.05$), compared with that of the normal control group. Sildenafil treatment exerted an intestinal anti-inflammatory effect, for 5 days, by a significant decrease in the weight/length ratio compared with that of the group (CC), ($p<0.05$).

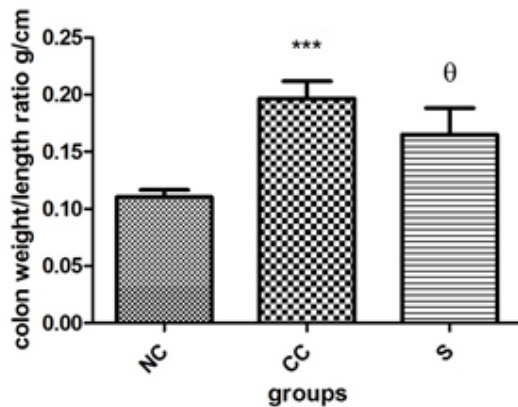


Figure 2. Effects of Sildenafil on colonic weight/length ratios.

Each column represented as the mean±SD.

*** Significant difference $P<0.05$, compared to the (NC) group; θ Significant difference $P<0.05$, compared to the (CC) group. (NC), control group; (CC), Acetic acid; (S), Sildenafil.

Effect of Sildenafil on GSH activities in colon tissues

The GSH level was used as an index of oxidative status in UC. The results demonstrated significantly reduced the concentration of endogenous antioxidant glutathione as compared to control group. Treatment of animals with Sildenafil significantly increased the glutathione concentration compared to acetic acid group ($p<0.05$).

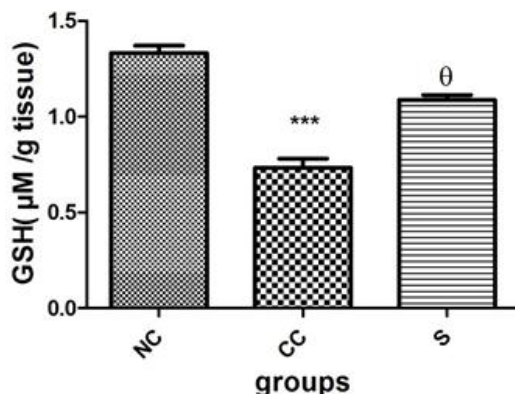


Figure 3. The effect of Sildenafil on GSH levels.

Data are presented as means ± SD (n =6). (NC); normal control, (CC); colitis control, (S); Sildenafil, groups.

*** Significant difference $P<0.05$, compared to the (NC) group; θ Significant difference $P<0.05$, compared to the CC group. NC, control group; (CC), Acetic acid; (S), Sildenafil.

Effects of Sildenafil on macroscopic scoring

The mucosa of rats in the normal group was smooth and intact. All acetic acid-treated rats showed injury to different extents, severe macroscopic damage of mucosa erosion and putrescence, multiulceration, which consisted of multifocal

lesions, such as thickening, haematoes or edema hemorrhagic areas, and necrotic of the proximal and distal colon Thus the morphological score in the (CC) group was significantly increased as compared to normal control group ($p<0.05$). Whilst, rats in the (S) group revealed improved macroscopical lesion with edema, haematoes mucosa, small and superficial ulcers, but the morphological score was not statistically significant as compared to (CC) group ($p<0.05$).

Table I. Macroscopic score of different experimental groups.

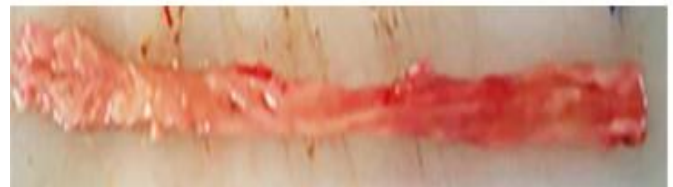Group Macroscopic Score	NC	CC	S
0	6(100%)	-	-
1	-	-	1(16.6%)
2	-	-	4(66.6%)
3	-	-	1(16.6%)
4	-	-	-
5	-	2(33.3%)	-
6	-	4(66.6%)	-



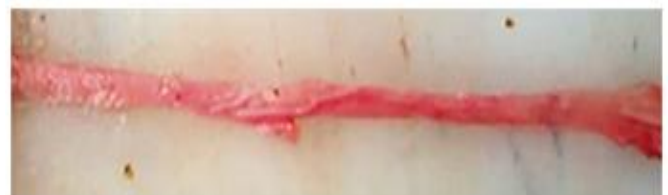A-(grade 0) showing normal mucosa



B-(grade 1) showing swelling or redness



C-(grade 2) showing swelling and redness



D-(grade 3) showing one or two ulcers



E-(grade 5) showing mild necrosis



F-(grade 6) showing severe necrosis

Figure 4. Macroscopic appearances of colons, (NC), normal group; (S), Sildenafil group; (CC), acetic acid group.

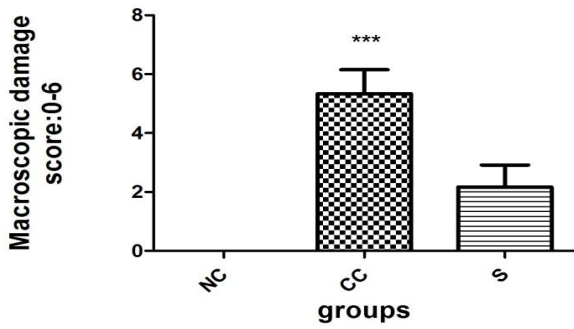


Figure 5. The effect of Sildenafil on macroscopic damage.

Data are presented as means ± SD (n =6). (N), normal control ;(CC), colitis control; (S) Sildenafil, groups.

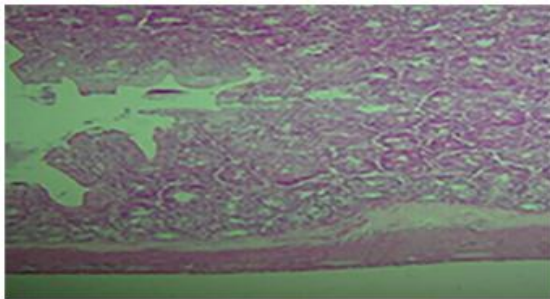
*** Significant difference $P < 0.05$, compared to the NC group.(NC), control group; (CC), Acetic acid; (S), Sildenafil.

Effect of Sildenafil on microscopic scoring in the colon tissues

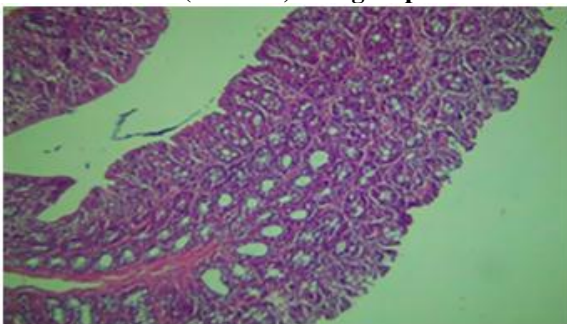
The colitis group had the highest histological score (3-4) which was characterized by severe disintegration of tissue architecture, massive inflammatory infiltration with large areas of ulceration. Histological sections displayed a loss of epithelia cells, reduction in the goblet cells, the collapse of crypts, ulcerations, submucosal edema, transmural distribution, and epithelial dysplasia. The histological score was significantly increased $p < 0.05$ vs. normal group. Conversely, the inflammation and damage in animals treated with Sildenafil were markedly improved, less necrosis and overall less visible changes compared to acetic acid control group. However, the values obtained with this dose of Sildenafil (10mg/kg) were not significantly different from the acetic acid control group.

Table II. Histological score of different experimental groups.

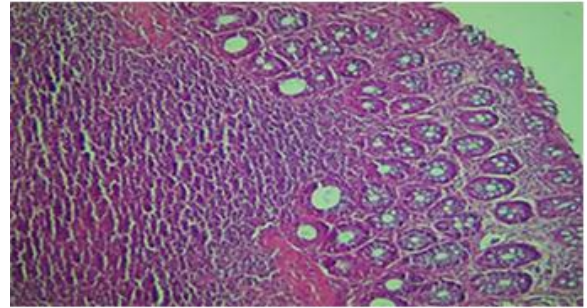
Group histological score	NC	CC	S
0	6(100%)	-	-
1	-	-	1(16.6%)
2	-	-	4(66.6%)
3	-	2(33.3%)	1(16.6%)
4	-	4(66.6%)	-



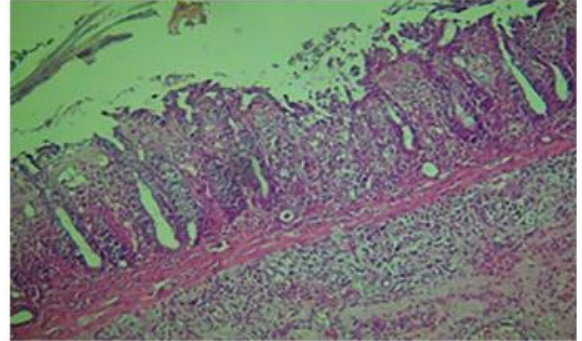
A- (Grade 0) NC group.



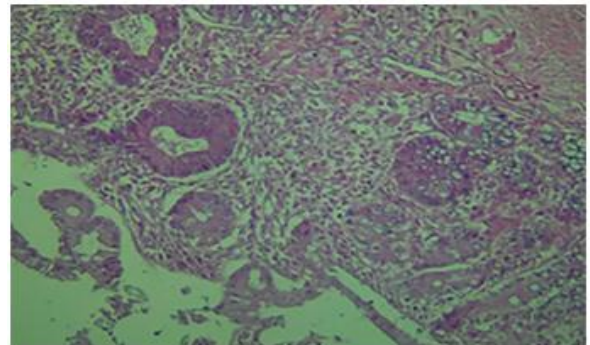
B- (grade 1) S group.



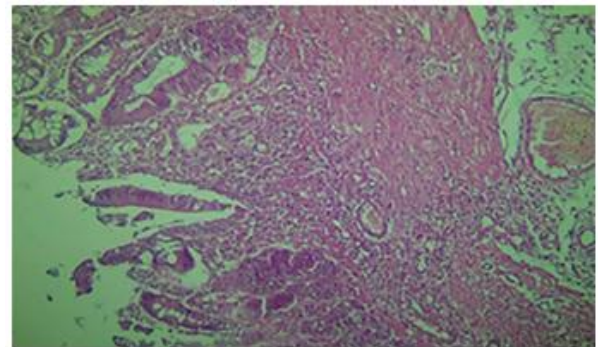
C- (grade 2) S group.



D- (grade 3) S group.



E- (Grade 4) CC group.



F- (Grade 4) CC group.

Figure 6. Histological appearance of colonic tissue sections, original magnification×10

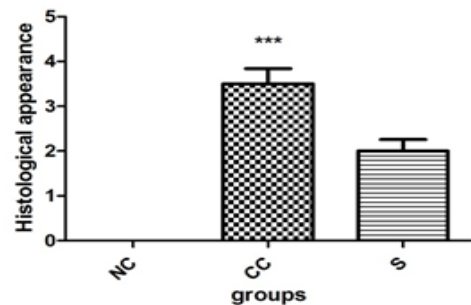


Figure 7. The effects of MSM on the histological changes in Acetic Acid induced ulcerative colitis in rats.

Parametric data were expressed as mean \pm S.D (n =6). (NC), normal control; (CC), colitis control;(S), Sildenafil group.

*** Significant difference as compared to normal control group at $p < 0.05$.

Discussion

Various animal models of experimental colitis have been designed and used to define the mechanisms of UC and to evaluate effective drugs for its treatment. Acetic acid-induced colitis, which is our model in this investigation, is an animal model that imitates some of the acute inflammatory responses of ulcerative colitis. Acetic acid-induced colitis is an easily and inducible model of inflammatory bowel disease (IBD), and the similarity of the inflammatory mediators' profile to IBD suggests that the inflammatory phase bears some resemblance to human intestinal inflammation [11].

In this study, the development of acetic acid-induced colitis was studied in relation to change of body weight (%), behavioral changes, weight/length (mg/cm) ratios of colon, tissue GSH levels, macroscopic, and histological features of inflamed tissue, which are used to quantify the severity of inflammation. In acetic acid treated animals (CC group), the severe colonic inflammatory reaction was associated with marked anorexia, severe diarrhea, and weight loss. Acetic acid caused a substantial degree of tissue injury associated with deep ulceration penetrating colonic wall through mucosa till muscularis mucosa, severe inflammation, and necrosis, associated with significant depletion in GSH levels, which is in agreement with the previous findings [21, 22].

Clinical observations have found that increased platelet number and platelet activation are notable characteristics of UC. Platelets can activate neutrophils and affect inflammatory status. These activated neutrophils produce and release several toxic reagents, such as reactive oxygen species (ROS) and protease, which can cause tissue damage [23]. Several studies found that excessive production of ROS in mucosal cells induced by inflammatory and immune responses could directly or indirectly cause damage of intestinal epithelial cells, subsequently influences the mucosal integrity or initiate an inflammatory signaling cascade and lead to severe impairment in experimental colitis [20]. In addition to the free radicals that are generated in the injured tissue, inflammatory cells which are recalled through chemotaxis to the target tissue play a pivotal role in the pathogenesis of the disease [24]. Free radicals contribute, aggravate and precipitate pathological changes in the colonic mucosa and have been proposed as therapeutic targets. Localized inflammation, neutrophil infiltration and the vicious cascade of generation of inflammatory mediators have been elucidated to damage the colonic mucosal [25]. reduced glutathione (GSH) inhibits ROS oxidative injuries directly *via* its sulfhydryl group and indirectly as a cofactor or a coenzyme in ROS enzymatic detoxification process [26].

Inflammation through the modification of the contractility of vascular and gut smooth muscle diminishes mucosal blood flow and eventually leads to tissue destruction. Histologically the intestinal inflammation is characterized by infiltration of polymorphonuclear leukocytes, monocytes, and macrophages. They are activated by various mediators including prostaglandins, leukotrienes, platelet activating factor, and cytokines to synthesize and liberate toxic reactive oxygen metabolites [11]. Increased levels of both TNF- α and PGE2, caused epithelial cell necrosis, edema, and neutrophil infiltration[21].

Furthermore, the role of the vasculature damage in mucosa and submucosa, and disturbances of blood flow are thought to be important pathogenic mechanisms in UC [27]. Results of the present study revealed, for the first time, that Sildenafil ameliorates acetic acid-induced colitis in rats. Sildenafil improved colonic macroscopic and histological damages, and increased significantly elevated tissue GSH, body weight, and colonic weight/length ratio. Sildenafil reversed the inflammatory parameters, it resulted in a dramatic reduction in diarrhea improved the animals' general condition and well-being, and increased GSH levels, therefore, Sildenafil can strengthen the enzymatic defensive system and reduce free radicals, then alleviate inflammation.

Neutrophils play a predominant role in inflammatory and immune reactions in inflammatory bowel disease [28].

Koupparis *et al.* have confirmed that the antioxygen free radical effect of sildenafil is mediated only by enhancing cGMP levels because the effect is blocked in the presence of guanylyl cyclase inhibitor [29]. In addition, it seems that sildenafil-induced reduction of free oxygen radical would, in turn, increase the bioavailability of nitric oxide. That, sildenafil indirectly mimics nitric oxide actions. Enhanced nitric oxide would further inhibit NADPH oxidase activity and expression. Regarding these interesting findings, sildenafil may be a potent inhibitor of superoxide formation in other tissues of the gut [11]. Sildenafil increases bowel total antioxidant capacity and cyclic nucleotides (cGMP, cAMP)[9].

Sildenafil exerts an anti-inflammatory response by normalizing the expression of inflammatory cytokines: (interleukin- 1 (IL-1) β , IL-6, IL-10, transforming growth factor β 1 (TGF β 1), oxidative stress factors Nicotinamide adenine dinucleotide phosphate (NADPH) oxidase, Myeloperoxidase (MPO), inducible nitric oxide synthase (iNOS), and TNF receptor superfamily member 5 (CD40) [30].

Sildenafil possesses gastroprotective activity, against indomethacin-induced gastric damage, by pretreatment with sildenafil 5,10 mg/kg, reduced gastric acid secretion, ulcer score and lipid peroxides production without effect on mucin, TNF- α , or nitric oxide (NO) [12]. As well as, pretreatment in doses of 1.5 or 3 mg/kg, 7 days before acetic acid [11].

The present investigation outlines the anti-inflammatory and antioxidant activities of Sildenafil against experimental ulcerative colitis. The anti-ulcerogenic effect was further confirmed by the histological preservation of the colon architecture and correlated to its anti-inflammatory properties. The positive effects of sildenafil in reducing tissue damages such as necrosis could possibly be attributed to the increase of colonic blood flow, and normalizing the expression of inflammatory cytokines by diminishing the production of damaging factors.

Conclusions

Based on the data obtained in this study, it can be confirmed that a dose of 10 mg of Sildenafil, has cured effects on acute experimental colitis, and its anti-inflammatory effects seem to be relative to antioxidation. Thus, this results showed that sildenafil has the potential to suppress colitis in rats. Results of proper clinical trials will determine the possible efficacy of phosphodiesterase-5 inhibitors in human UC .

References

- [1] B.G.Schwartz, L.A. Levine, G. Comstock, V.J. Stecher, R.A.K. loner, Cardiac uses of phosphodiesterase-5 inhibitors, *Journal of the American College of Cardiology*, 59 (2012) 9-15.
- [2] A.P.A. Costa, A.M.V. Lima, L.H. da Silva, R.d.O.A. Carvalho, A.V.C. do Amaral, N.C. Borges, Ocular perfusion pressure and color Doppler imaging of the external ophthalmic artery of rabbits treated with sildenafil citrate, *BMC Veterinary Research*, 12 (2016) 1.
- [3] J.D. Peuler, L.E. Phelps, Sildenafil does not enhance but rather attenuates vasorelaxant effects of antidiabetic agents, *Journal of Smooth Muscle Research*, 51 (2015) 22-36.
- [4] W. Dai, R.A. Kloner, Is inhibition of phosphodiesterase type 5 by sildenafil a promising therapy for volume-overload heart failure?, *Circulation*, 125 (2012) 1341-1343.
- [5] S.E. Ferreira-Melo, J.C. Yugar-Toledo, O.R. Coelho, I.M. De Luca, J.E. Tanus-Santos, S. Hyslop, M.C. Irigoyen, H. Moreno, Sildenafil reduces cardiovascular remodeling associated with hypertensive cardiomyopathy in NOS inhibitor-treated rats, *European journal of pharmacology*, 542 (2006) 141-147.
- [6] A. Das, D. Durrant, F.N. Salloum, L. Xi, R.C. Kukreja, PDE5 inhibitors as therapeutics for heart disease, diabetes and cancer, *Pharmacology & therapeutics*, 147 (2015) 12-21.
- [7] A.K. de Santana Nunes, C. Rapôso, U. Björklund, M.A. da Cruz-Höfling, C.A. Peixoto, E. Hansson, Sildenafil (Viagra®) prevents and restores LPS-induced inflammation in astrocytes, *Neuroscience Letters*, 630 (2016) 59-65.
- [8] A. Küçük, M. Yucel, N. Erkasap, M. Tosun, T. Koken, M. Ozkurt, S. Erkasap, The effects of PDE5 inhibitory drugs on renal ischemia/reperfusion injury in rats, *Molecular biology reports*, 39 (2012) 9775-9782.
- [9] M.J. Zamani, M. Sharifzadeh, A. Rezaie, F. Mashayekhi, M. Abdollahi, Effects of sildenafil on rat irritable bowel syndrome, (2005).
- [10] M. Bortolotti, C. Mari, C. Lopilato, L. La Rovere, M. Miglioli, Sildenafil inhibits gastroduodenal motility, *Alimentary pharmacology & therapeutics*, 15 (2001) 157-161.
- [11] P. Khoshakhlagh, M. Bahrololoumi-Shapourabadi, A. Mohammadirad, L. Ashtaral-Nakhai, B. Minaie, M. Abdollahi, Beneficial effect of phosphodiesterase-5 inhibitor in experimental inflammatory bowel disease; molecular evidence for involvement of oxidative stress, *Toxicology mechanisms and methods*, 17 (2007) 281-288.
- [12] Y. Moustafa, D. Khoder, E. El-Awady, S. Zaitone, Sildenafil citrate protects against gastric mucosal damage induced by indomethacin in rats, *Eur Rev Med Pharmacol Sci*, 17 (2013) 179-188.
- [13] S.B. Hanauer, Inflammatory bowel disease: epidemiology, pathogenesis, and therapeutic opportunities, *Inflammatory bowel diseases*, 12 (2006) S3-S9.
- [14] C. Zeng, J.-H. Xiao, M.-J. Chang, J.-L. Wang, Beneficial effects of THSG on acetic acid-induced experimental colitis: involvement of upregulation of PPAR- γ and inhibition of the Nf-Kb inflammatory pathway, *Molecules*, 16 (2011) 8552-8568.
- [15] H.H. Hagar, A. El Medany, E. El Eter, M. Arafa, Ameliorative effect of pyrrolidinedithiocarbamate on acetic acid-induced colitis in rats, *European journal of pharmacology*, 554 (2007) 69-77.
- [16] A. Tüzün, A. Erdil, V. İnal, A. Aydın, S. Bağcı, Z. Yeşilova, A. Sayal, N. Karaeren, K. Dağalp, Oxidative stress and antioxidant capacity in patients with inflammatory bowel disease, *Clinical biochemistry*, 35 (2002) 569-572.
- [17] K. Amirshahrokhi, S. Bohlooli, M. Chinifroush, The effect of methylsulfonylmethane on the experimental colitis in the rat, *Toxicology and applied pharmacology*, 253 (2011) 197-202.
- [18] A. Millar, D. Rampton, C. Chander, A. Claxson, S. Blades, A. Coumbe, J. Panetta, C. Morris, D. Blake, Evaluating the antioxidant potential of new treatments for inflammatory bowel disease using a rat model of colitis, *Gut*, 39 (1996) 407-415.
- [19] C. Blenn, F.R. Althaus, M. Malanga, Poly (ADP-ribose) glycohydrolase silencing protects against H₂O₂-induced cell death, *Biochemical Journal*, 396 (2006) 419-429.
- [20] B. Medhi, A. Prakash, P. Avti, U. Saikia, P. Pandhi, K. Khanduja, Effect of Manuka honey and sulfasalazine in combination to promote antioxidant defense system in experimentally induced ulcerative colitis model in rats, *Indian journal of experimental biology*, 46 (2008) 583.
- [21] H.S. El-Abhar, L.N. Hammad, H.S.A. Gawad, Modulating effect of ginger extract on rats with ulcerative colitis, *Journal of ethnopharmacology*, 118 (2008) 367-372.
- [22] A. Cetinkaya, E. Bulbuloglu, E.B. Kurutas, H. Ciralik, B. Kantarceken, M.A. Buyukbese, Beneficial effects of N-acetylcysteine on acetic acid-induced colitis in rats, *The Tohoku journal of experimental medicine*, 206 (2005) 131-139.
- [23] J.-F. Xing, J.-N. Sun, J.-Y. Sun, S.-S. Hu, C.-N. Guo, M.-L. Wang, Y.-L. Dong, Protective effect of shikimic acid on acetic acid induced colitis in rats, *Journal of Medicinal Plants Research*, 6 (2012) 2011-2018.
- [24] M.H. Sanei, F. Hadizadeh, P. Adibi, S.A. Alavi, Inflammatory cells' role in acetic acid-induced colitis, *Advanced biomedical research*, 3 (2014).
- [25] W. Strober, I.J. Fuss, Proinflammatory cytokines in the pathogenesis of inflammatory bowel diseases, *Gastroenterology*, 140 (2011) 1756-1767. e1751.
- [26] S.S. Al-Rejaie, H.M. Abuhashish, M.M. Al-Enazi, A.H. Al-Assaf, M.Y. Parmar, M.M. Ahmed, Protective effect of naringenin on acetic acid-induced ulcerative colitis in rats, *World J Gastroenterol*, 19 (2013) 5633-5644.
- [27] O.A. Hatoum, H. Miura, D.G. Binion, The vascular contribution in the pathogenesis of inflammatory bowel disease, *American Journal of Physiology-Heart and Circulatory Physiology*, 285 (2003) H1791-H1796.
- [28] T. SAIKI, Myeloperoxidase concentrations in the stool as a new parameter of inflammatory bowel disease, *The Kurume medical journal*, 45 (1998) 69-73.
- [29] A.J. Koupparis, J.Y. Jeremy, S. Muzaffar, R. Persad, N. Shukla, Sildenafil inhibits the formation of superoxide and the expression of gp47phox NAD [P] H oxidase induced by the thromboxane A₂ mimetic, U46619, in corpus cavernosal smooth muscle cells, *BJU international*, 96 (2005) 423-427.
- [30] L.A. Garcia, S.M. Hlaing, R.A. Gutierrez, M.D. Sanchez, I. Kovanecz, J.N. Artaza, M.G. Ferrini, Sildenafil attenuates inflammation and oxidative stress in pelvic ganglia neurons after bilateral cavernosal nerve damage, *International journal of molecular sciences*, 15 (2014) 17204-17220.