



# الجامعة السورية الخاصة كلية الطب

## Key communication skills and how to acquire them

M.A.Kubtan , MD-FRCS

Lectur 5

# Cardiovascular Examination

- W** - Wash your hands.
- I** - Introduce yourself to the patient.
- P** - Permission. Explain that you wish to examine their heart. Obtain consent for the examination. Pain. Ask the patient if they are in any pain and to tell you if they experience any during the examination.
- E** - Expose the necessary parts of the patient. Ideally the patient should be undressed from the waist up taking care to ensure the patient is not cold or unnecessarily embarrassed.
- R** - Reposition the patient. In this examination the patient should be supine and reclined at 45 degrees.

# Clinical Examination

1. Peripheral Examination .
2. Precodrium Examination .

# Peripheral Examination

## End of the bed .

First examine the patient at the end of the bed for signs of breathlessness or distress.

It is also important to look at the surrounding environment for oxygen, fluid restriction signs or GTN spray.

# Hands

Take the patient's hand and assess warmth, sweating and whether there is peripheral cyanosis.

Check the capillary refill (press the end of the finger for 5 seconds, release and see how long it takes the colour to return. It should be less than 2 seconds).

Examine the nails for clubbing or signs of infective endocarditis (splinter haemorrhages, Osler's nodes).

# Pulse & Rhythm

Palpate the radial pulse and assess the rate and rhythm.

Locate and palpate the brachial pulse and assess its character.

Measure the blood pressure. If the blood pressure is raised compare both arms

# Look at Face

Check eyes for corneal arcus and xanthelasma.

Inspect the conjunctiva for signs of anaemia.

Check for mouth and tongue for central cyanosis.

Assess the jugular venous pressure height and wave

Palpate the carotid pulse and assess its character.

# Examination of Precordium

## Inspection

Inspect the chest wall :

- Previous Scars .
- Pacemaker .
- Abnormal Pulsation .
- A visible Apex Beat .



# Examination of Precordium

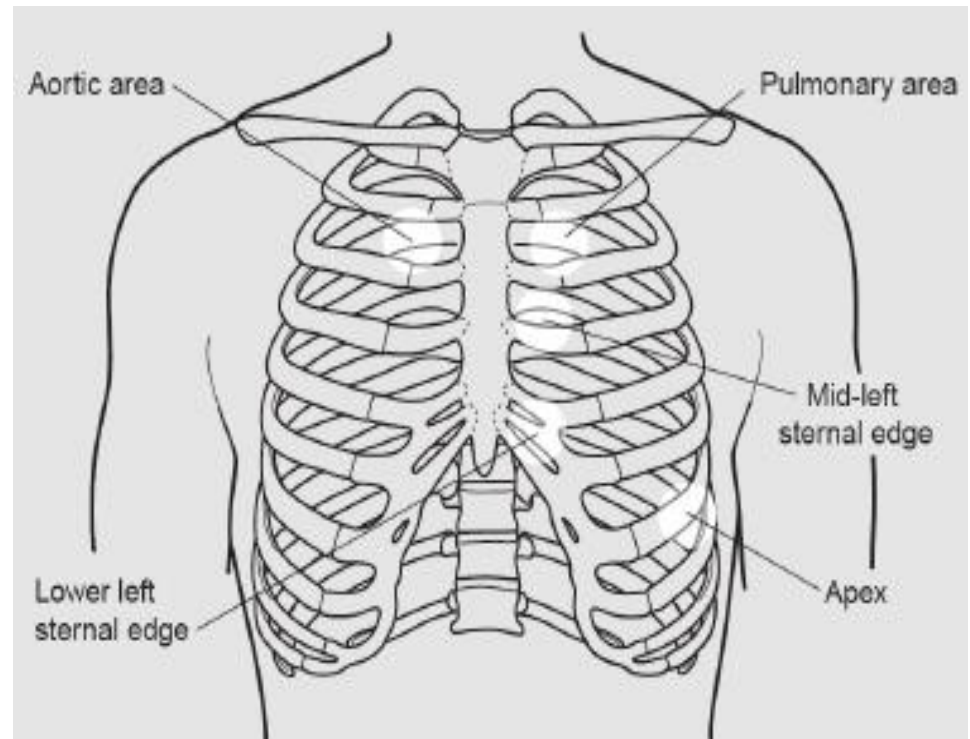
## Palpation

Palpate for

- Apex beat , Location ,Quality of Impulse .
- Heaves ( تنهد ، سحب ) , Forceful Ventricular contraction
- Heaves represent Ventricular Hypertrophy  
( Feel as if your hand being lifted of the patients chest ) .
- Thrills , palpable mummies ( Stroking a purring cat ) .

# Examination of Precordium

- **Percussion** : usually not performed .
- **Auscultation** :  
Heart Sounds .  
Murmurs.  
Rhythm .



# Finishing of

State that you would complete the examination by:

- Auscultating the lung bases posteriorly for pulmonary oedema
- Checking for sacral and ankle oedema
- Checking the peripheral pulses – femoral, popliteal, posterior tibial & dorsalis pedis.
- Check for an abdominal aortic aneurysm